







REVIEW

Direct aspiration stroke thrombectomy: a comprehensive review

William Boisseau,¹ Simon Escalard,¹ Robert Fahed ,^{1,2} Bertrand Lapergue,³ Stanislas Smajda ,¹ Benjamin Maier,^{1,4} Jean Philippe Desilles,^{1,4} François Delvoye ,¹ Gabriele Ciccio,¹ Hocine Redjem,¹ Solène Hebert,¹ Malek Ben Maacha,¹ Gregory Walker,^{2,5} Benjamin Gory ,⁶ Sébastien Richard,⁷ Mikael Mazighi,^{1,4} Michel Piotin ,^{1,4} Raphaël Blanc ,^{1,4}

► Additional material is published online only. To view please visit the journal online (<http://dx.doi.org/10.1136/neurintsurg-2019-015508>).

For numbered affiliations see end of article.

Correspondence to

Dr Raphaël Blanc, Département de interventionnel neuroradiologie, Fondation Ophtalmologique Adolphe de Rothschild, Paris, Île-de-France, France; rblanc@for.paris

Received 5 March 2020
Revised 22 April 2020
Accepted 29 April 2020
Published Online First
12 June 2020

ABSTRACT

Mechanical thrombectomy is now the standard of care for acute ischemic stroke patients with large vessel occlusions, and can be performed with several devices and techniques. One of these techniques, direct aspiration (DA), consists of navigating a large-bore catheter up to the face of the clot and initiating forceful suction. This comprehensive review has three objectives: (1) to describe the direct aspiration technique; (2) to present the available evidence regarding predictive factors of DA success and performance compared with other techniques; and (3) to discuss the forthcoming improvements in distal aspiration.

INTRODUCTION

With the results from recent randomized clinical trials (RCT),^{1,2} the clinical benefit of mechanical thrombectomy (MT) in patients with acute ischemic stroke and anterior circulation large vessel occlusion (AC-LVO) is now well established. This benefit over best medical therapy alone was in large part due to the achievement of excellent recanalization rates and the demonstration of safety of the thrombectomy procedure. Although MT is now standard of care, there is still ongoing debate regarding the optimal first-line thrombectomy strategy. The most commonly used device in these trials was the stent retriever (SR) and, as a result, it is generally felt to be the first-line device for MT.^{3,4} Alternative techniques such as a direct aspiration first-pass technique (ADAPT) or direct aspiration (DA) are being increasingly used in current clinical practice. These techniques involve the use of large-bore aspiration catheters that are guided to the proximal end of the thrombus and then put under negative pressure (by using vacuum aspiration systems or a syringe) to produce suction on the thrombus. The clot is thus trapped at the tip or aspirated through the aspiration catheter.⁵

Over the past several years, clinical experiences reported in several non-controlled observational studies^{6,7} have suggested that compared with SRs, DA could result in faster reperfusion, higher rates of successful reperfusion (defined by a Thrombolysis in Cerebral Infarction (TICI) score of 2b or more), lower rates of major complications (including fewer distal emboli⁸ and vessel wall damages⁹) and

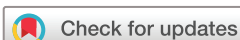superior cost effectiveness.¹⁰ Similar results have been reported for basilar artery occlusion (BAO)^{11,12} and M2 occlusions.^{13,14} However promising these results may seem, they were not confirmed by two recent randomized controlled trials, ASTER¹⁵ (Contact Aspiration vs Stent Retriever for Successful Revascularization) and COMPASS¹⁶ (Aspiration Thrombectomy vs Stent Retriever Thrombectomy as First-Line Approach for Large Vessel Occlusion), that only demonstrated similar efficacy and safety.

Notably, DA has also been used in combination with SR. Several techniques using the combination of SR and DA have been described: Solumbra (which refers to Solitaire (Medtronic Neurovascular, Irvine, CA) and Penumbra combination),¹⁷ ARTS (Aspiration (catheter)-(stent) Retriever Technique for Stroke),¹⁸ and SAVE (Stent retriever Assisted Vacuum-locked Extraction) are some examples.¹⁹ Again, although several observational studies have reported promising results with such a combined approach,²⁰ no clear superiority over DA has been shown in an RCT.²¹

This comprehensive review has three objectives: (1) to perform a description of the direct aspiration technique; (2) to present the available evidence regarding predictive factors of DA success and performance compared with other techniques; and (3) to discuss the forthcoming improvements in distal aspiration.

TECHNIQUE AND DEVICE EVOLUTIONS OF DIRECT ASPIRATION

The index experience with aspiration in patients with AC-LVO was published in 2006.²² In this prospective single-arm trial, complete or partial recanalization was obtained in only seven of 14 patients and only six patients experienced good functional outcome at 3 months. This first experience was followed by the publication of two other studies in 2008²³ and 2009²⁴ in which an aspiration catheter was used in combination with a device separator to fragment and remove the clot. However, despite excellent recanalization rates with these devices, clinical results were modest. In the Penumbra Pivotal Stroke Trial, while 82% of these patients achieved a Thrombolysis In Myocardial Infarction (TIMI) score of 2 or 3, only 25% of patients had a modified Rankin Scale (mRS) score



© Author(s) (or their employer(s)) 2020. No commercial re-use. See rights and permissions. Published by BMJ.

To cite: Boisseau W, Escalard S, Fahed R, et al. *J Neurol Interv Surg* 2020;**12**:1099–1106.

Table 1 List and characteristics of new generation of large-bore aspiration catheters

Product name	Length (cm)	Proximal OD (inches)	Proximal ID (inches)	Distal ID (inches)	FDA approved	CE approved
PENUMBRA (Alameda, CA)						
ACE 68	132	0.080	0.068	0.068	X	X
JET 7	132	0.085	0.072	0.072	X	Pending
STRYKER (Fremont, CA)						
CATALYST 7	132	NA	0.068	0.068	X	X
VECTA	132	0.085	0.071	0.071	X	X
MICROVENTION (Tustin, CA)						
SOFIA 6F FLOW PLUS	125/131	0.0825	0.070	0.070	X	X
MEDTRONIC (Irvine, CA)						
REACT 68	132	0.083	0.068	0.068	X	X
REACT 71	132	0.0855	0.071	0.071	X	X

CE, European conformity; FDA, US Food and Drug Administration; ID, inner diameter; OD, outer diameter.

≤2 at 90 days.²⁴ Missing data (including initial Alberta Stroke Program Early CT Score (ASPECTS), time from onset to recanalization, and procedural time) may have explained the lack of clinical response in some patients despite recanalization.

In the years that followed, technological improvements led to the development of new aspiration catheters with larger distal internal diameter, a softer tip, and better navigability and trackability into the distal anatomy. Together, these features allowed operators to reach the intracranial clot and aspirate it without the need for a separator device, a technique called Forced Aspiration Suction Thrombectomy (FAST).²⁵ In 2012,

The Randomized Concurrent Controlled Trial to Assess the Penumbra System's Safety and Effectiveness in the Treatment of Acute Stroke (THERAPY trial) began.²⁶ THERAPY compared DA plus intravenous tissue plasminogen activator (IV tPA) versus IV tPA alone. This trial was halted early, after the publication of five RCTs confirming the efficacy of MT with SR. Based on the analysis of the 108 patients recruited into this study, patients treated with DA and IV tPA did not achieve better clinical outcomes (mRS 0–2) in comparison with IV tPA alone (38% vs 30%, $p=0.44$).²⁶ Thus, although there is compelling evidence that MT with SR is superior to best medical therapy, there are no comparable data for DA.

In 2014, a new aspiration technique, ADAPT, emerged.⁵ This technique, using a new generation of large-bore aspiration catheters, has gradually evolved further over subsequent years, with the development of even larger aspiration catheters (a new generation of large-bore aspiration catheters and characteristics are summarized in table 1). In the next paragraph, we delineate a step-by-step description of the DA technique based on our experience and techniques reported in the literature.

A guiding catheter (long introducer sheath or a balloon guide catheter (BGC) for proximal flow arrest) is navigated into the target proximal cervical vessel (carotid or vertebral artery). With the help of a microcatheter and a microwire, a large bore aspiration catheter is then navigated intracranially up to the proximal portion of the clot. Once in place, the aspiration catheter is then connected to an aspiration system such as a pump or a negative-pressure syringe. After waiting for a few minutes, the aspiration catheter is then slowly withdrawn (figure 1). Several important features need to be considered here:

- Some of the latest generation aspiration catheters are so flexible that, in some favorable anatomical configurations, they can be navigated without a microcatheter (with a microwire only), or even with no device at all,²⁷ which can speed up the procedure.²⁷
- When using a microcatheter and/or a microwire to navigate the aspiration catheter, it is recommended to avoid crossing the thrombus whenever possible, as it may be associated with an increased risk of causing distal emboli. Once the aspiration catheter is in contact with the proximal end of the thrombus (within 2–3 mm of the thrombus if possible), the microcatheter should be removed before initiating suction.²⁸ Of note, even an optimal positioning of the aspiration

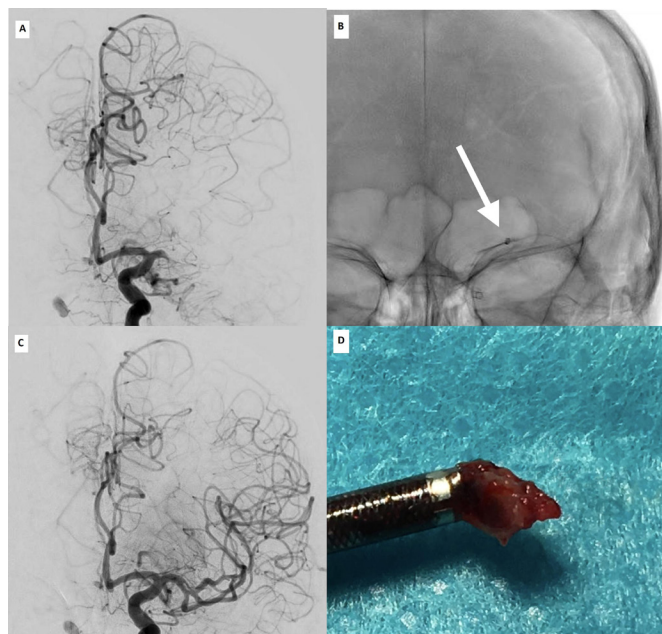


Figure 1 Illustrative case of the direct aspiration technique. Patient presenting 3 hours after acute onset of right-side hemiparesis and aphasia (NIHSS score of 25). Baseline angiography (A) shows total occlusion of the segment M1 of the left MCA. (B) Distal part of the Sofia plus aspiration catheter (white arrow) in contact with the proximal end of the thrombus. (C) Final angiography shows complete reperfusion (TICI 3) after first pass. (D) Whole clot is trapped at the tip of the aspiration catheter. MCA, middle cerebral artery; NIHSS, National Institutes of Health Stroke Scale; TICI, Thrombolysis in Cerebral Infarction.

catheter, with clear engagement of the clot, does not ensure technical success, as the clot may stay in place.

- There is no consensus regarding the optimal duration after suction activation from which the catheter should be removed. Catheter removal is typically done after 2–3 min of continuous aspiration.
- Once the aspiration catheter is in place, and the suction activated, it is essential to observe the behavior of the aspiration tube or syringe:

The presence of an immediate backflow could either indicate that the aspiration catheter is not properly placed (usually too proximal to the clot) or the clot has been successfully aspirated (in this case the clot could be seen in the syringe or going through the aspiration tube).

If there is no backflow until the catheter is removed from the patient, it is likely that the clot (or at least a portion of it) is occlusive, inside the catheter or at its tip.

If backflow is restored before the catheter is removed from the long introducer sheath or the BGC, it is likely that the clot was aspirated in the process, or that it was lost on withdrawing the aspiration catheter and remains in the vasculature. In this situation, it is not necessary to completely remove the aspiration catheter, and it may be advantageous to keep the catheter in the patient in the event another pass is required. However, the operator must take great care with the control run as the force of the injection could push residual clot back into the distal vessels.

FACTORS INFLUENCING THE SUCCESS OF DIRECT ASPIRATION

Technical factors

A greater aspiration force is one of the most frequently reported factors that may positively influence the success of DA. Several technical factors have been shown to impact aspiration force and, as a result, recanalization. A larger inner diameter (ID) of the aspiration catheter^{6 29} is a critical factor. For example, the use of ACE 68, which could generate 25% greater aspiration force than the ACE 60^{6 29} compared with smaller aspiration catheters (ACE 60 and 5Max, Penumbra, Alameda, CA) has been shown to lead to a higher rate of successful reperfusion after the first pass. This was associated with shorter procedural times and lower rates of rescue treatment with SR without increased risk of complications.^{6 29} Removing the microcatheter before suction has also been shown to influence aspiration force.²⁸ Finally, using a vacuum aspiration system with higher aspiration force³⁰ has also been beneficial.

In addition to the aspiration force, the use of cyclical aspiration instead of continuous aspiration could result in higher first-pass recanalization rates and lower distal clot embolization.^{31 32} One hypothesis is that cyclical aspiration allows larger clot ingestion into the aspiration catheter and causes less clot fragmentation than continuous aspiration.³¹ Although DA could be used with either a long introducer sheath or a BGC, recent retrospective studies have shown that utilization of a BGC might improve the final and first-pass recanalization rates.³³ One possible explanation is that inflation of the BGC might reduce the systolic blood pressure acting on the proximal clot face, thus enhancing the effect of aspiration.³³

Anatomical factors

The reviewed literature describes the site of arterial occlusion (with isolated middle cerebral artery (MCA) occlusion being the best target for DA),³⁴ and the angle of interaction between the

aspiration catheter and the clot,³⁵ as being important factors for DA success. In one study, an angle of interaction between the aspiration catheter and the clot of $\geq 125.5^\circ$ was significantly associated with successful clot removal.³⁵ One explanation for this may be that a low angle of interaction between the aspiration catheter and the clot might be associated with a much higher coefficient of friction acting on the thrombus, leading to increased resistance to DA.

Patient factors

Younger age³⁶ and a shorter time from stroke onset to clot contact³⁴ have been reported to positively influence the success of aspiration. One speculative explanation for the latter finding could be that a longer delay since stroke onset might promote biological interactions between the thrombus and the arterial wall, leading to a more firm adhesion which could then explain DA failure.

Clot related factors

Several studies have reported that clot composition (ie, fibrin and red blood cell (RBC) content) could have an impact on the success of aspiration.^{37 38} These studies suggest that the DA technique may be more efficient for fibrin-rich clots which could correspond to clots with low density on CT scan and without susceptibility vessel sign (SVS) on MRI.^{37 39} Higher recanalization rates may be achieved with SR for an RBC-rich clot which might correspond to clots with high density on CT scan and with SVS on MRI.^{38 39} This hypothesis is to be tested in the VECTOR trial,⁴⁰ an RCT which will compare the combined approach to DA alone as first line for patients with a positive SVS on MRI.

DIRECT ASPIRATION VERSUS OTHER TECHNIQUES

Methods

Literature search

We performed a literature search through MEDLINE/PubMed and Google Scholar for papers published in the English literature from 2015 to 2020 using the following search key:

“ADAPT”, “aspiration”, “contact aspiration”, “stent”, “stent retriever”, “acute ischemic stroke”, “mechanical thrombectomy”, “endovascular treatment”, “outcome” and “revascularization”. Additional studies were identified through a manual search of the references of published papers and reviews.

Two authors (WB and RB) carried out the literature search and extracted data from relevant studies. Studies comparing clinical and/or angiographic outcomes between DA and SR or the combined approach were included. Exclusion criteria were: (1) case reports; (2) studies not separating outcomes by first-line device use; (3) non-comparative studies (ie, studies with a single group); and (4) studies published before 2015 and the use of new generation of stent retriever and large-bore aspiration catheters.

Outcome variables

For the purposes of this study, patients were divided into three groups according to the first-line device use: SR, DA, and the combination of both techniques. The following outcomes were studied: good functional outcome defined as an mRS ≤ 2 at 90 days following endovascular treatment, mortality, successful recanalization defined as TICI 2b/3, complete recanalization (TICI 3), first pass recanalization rates defined as complete recanalization with a single thrombectomy device pass, and procedure duration (ie, delay between puncture and recanalization). Results were divided into three groups according to the occlusion location: AC-LVO (intracranial internal carotid artery, M1 or

Ischemic Stroke

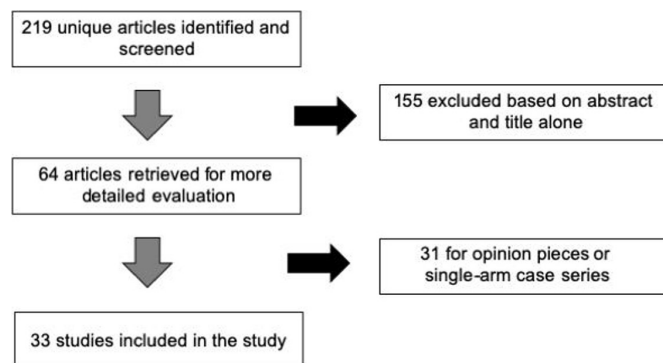


Figure 2 PRISMA flow diagram. PRISMA, Preferred Reporting Items for Systematic Reviews and Meta-Analyses.

proximal M2 branches of the MCA), basilar artery, and medium vessel occlusions (MeVOs) (ie, distal M2 or M3 segments of the MCA, pericallosal artery or the posterior cerebral artery).⁴¹

RESULTS

A total of 219 articles were retrieved after the first round of research, 155 of which were excluded by title or abstract screening. The full texts of the remaining 64 articles were accessed, and 33 articles matching the inclusion criteria were included: 26 studies with AC-LVO (including 20 studies comparing DA and SR and six comparing DA and the combined approach), six studies with BAO, and one study with MeVOs. The search selection process is illustrated in figure 2.

Anterior circulation large vessel occlusion

Direct aspiration versus stent retriever first-line technique

The 15 selected studies included five observational studies,^{7 42–45} two RCTs (ASTER¹⁵ and COMPASS¹⁶) and eight systematic reviews and meta-analyses.^{46–53} Study characteristics are summarized in online supplementary table 1. Devices, and clinical and angiographic outcomes, are depicted in table 2.

The majority of these studies demonstrated similar successful (TICI 2b or more) and complete (TICI 3) reperfusion rates, both after the first-line strategy and at the end of the procedure.^{15 16 42–44} Successful reperfusion rates ranged from 42–83% after first-line DA, and from 78–92% at the end of the procedure.^{7 15 16 42 44} These studies also reported similar adverse events rates (including symptomatic intracranial hemorrhage (sICH) and embolization in a new territory (ENT)) and clinical outcomes with both techniques.^{7 15 16 42} Nevertheless, several studies^{7 43 45} and meta-analyses^{49 52} have suggested that the proportion of patients who needed rescue therapies was higher among patients who received first-line DA. A similar result was found in the ASTER trial in which 32.8% of patients treated with DA received rescue treatment compared with 23.8% in the SR group (OR 1.57, 95% CI 0.99 to 2.47; $p=0.05$).¹⁵

Finally, studies have suggested several advantages of DA over SR as a first-line strategy. Total device cost seems to be significantly lower with DA. In the recent COMPASS trial, the use of DA as first-line approach led to a mean reduction of \$5074 in the cost of devices used.¹⁶ DA was also associated with faster groin-to-reperfusion time.^{16 42–45} According to the ASTER and COMPASS trials, DA resulted in a shorter mean procedural time of 7–10 min compared with SR.^{15 16} Despite this time advantage, DA was not associated with improved patient outcomes. Similar results have been reported in studies focusing on patients with

proximal M2 occlusions only (three observational studies and two meta-analyses) (see table 3).^{54–58}

It should be noted that several of the aforementioned studies included patients before 2015, at a time when MT was not yet standard of care; thus these studies reflect data accrued with older generations of devices, with older techniques and without the rigorous patient selection criteria responsible for the great success in recent trials. Furthermore, these early studies were plagued with a significant heterogeneity in thrombectomy technique which confounds comparison between SR and DA. In some studies, the concomitant use of a DA in the stent retriever first-line group was frequent. In the COMPASS trial¹⁶ 85% of patients in the SR group also received DA, as did 55.7% of SR patients in the study by Stapleton *et al.*⁴⁴ In the ASTER trial, only 2.9% of the SR group also had DA.¹⁵ As a consequence, many SR patients were not in fact SR-only patients but rather patients treated with a combined approach. In similar fashion, the use of BGCs with SR was not standardized in several studies, introducing another level of heterogeneity.^{7 15 16 42–44} While BGCs were systematically used with SR in the ASTER trial,¹⁵ they were used between 0–72% of cases in other studies.^{7 16 42–44} Finally, many DA studies included patients treated with intermediate-size aspiration catheters (which, as described above, might not be as efficient as larger-bore aspiration catheters). Only the COMPASS¹⁶ study used predominantly large-bore aspiration catheters (with ID ≥ 0.064 inches). In COMPASS,¹⁶ 98% of patients in the DA first-line group were treated with large-bore catheters compared with only 47.7% in the ASTER study.¹⁵ Although future RCTs will be required to confirm these findings, it is reasonable to speculate that better reperfusion rates could have been reached with the use of these larger-bore aspiration catheters.

Direct aspiration versus combined approach

Ten studies compared DA alone versus the combined treatment (combination of DA and SR) in patients with AC-LVO. Six of these studies used the combined approach as a rescue treatment (after the failure of first-line DA) and not as first-line technique and were thus excluded.

Our review thus includes four observational studies^{10 20 59 60} and one RCT,²¹ a non-inferior randomized multicenter study comparing the effects of a three-dimensional stent retriever in conjunction with local aspiration-based mechanical thrombectomy versus aspiration-based thrombectomy alone as a primary modality for endovascular stroke intervention. Three of these studies^{10 20 21} have been pooled in a recent meta-analyses.⁶¹ Study characteristics are summarized in online supplementary table 1. Details of the revascularization devices as well as the clinical and angiographic outcomes are reported in table 4.

According to this recent meta-analysis,⁶¹ combined treatment was associated with better successful reperfusion rates (OR 1.47, 95% CI 1.02 to 2.12) compared with DA alone; however, there was no difference in clinical outcomes (favorable outcome OR 0.84, 95% CI 0.38 to 1.86). One study⁵⁹ further investigated this result. After stratification according to the occlusion site, the combined approach was more efficient for carotid “T” occlusions with higher rates of recanalization (TICI 2c or more 55.2% vs 15.4%; $p=0.025$), with higher rates of first-pass mTICI 2c or more (59.6% vs 33.3%; $p=0.019$), and demonstrated a trend toward better final successful reperfusion rate (93.1% vs 65.4%; $p=0.10$).⁵⁹ For M1 segment occlusion, similar reperfusion rates were reported (94.8% vs 83.3%; $p=0.187$). Finally, two observational studies have also reported a lower rate of ENT with combined treatment but also an increased risk of sICH,^{20 60} a difference that was not found in the RCT.²¹ There is an ongoing RCT which may help to confirm

Table 2 Angiographic and clinical outcomes in patients with AC-LVO treated with DA or SR as first-line device

Ref	Device	% M1 occlusion	% catheter with ID >0.064	% with aspiration	After first line				At the end		Median procedural time (min)	% use of rescue therapy	Complications		
					% with BGC	% TICI >2b	% TICI 3	% FPE	% TICI >2b	% TICI 3			ENT	sICH	% mRS 0–2
Laperque 2016	DA	71.2%	0%	100%	0%	NA	NA	NA	82.3%*	NA	45	45.2%*	5.7%	2.4%	53.0%
	SR	0%	0%	0%	100%	NA	NA	NA	68.9%*	NA	50	13.5%*	6.8%	5.9%	54.8%
Laperque 2017	DA	57.1%	47.7%	100%	0%	63.0%	28.7%	NA	85.4%	37.5%	38	32.8%	5.3%	5.3%	45.3%
	SR	59.1%	NA	2.9%	100%	67.7%	35.5%	NA	83.1%	38.6%	45	23.8%	8.5%	6.5%	50.0%
Stapleton 2018	DA	70.2%	NA	100%	0%	46.8%	NA	NA	83%	NA	54*	42.6%	NA	12.8%	48.9%
	SR	61.4%	NA	55.7%	0%	NA	NA	NA	71.4%	NA	77*	NA	NA	10%	41.4%
Benson 2018	DA	54%	NA	NA	25%	NA	NA	52%	63%	35%	56.5*	22%	2%	9%	39%
	SR	59%	NA	NA	72%	NA	NA	47%	56%	29%	70*	26%	2%	6%	38%
Martini 2019	DA	72.0%	NA	NA	NA	65.7%	NA	NA	91.2%	NA	28.2*	33%*	NA	NA	NA
	SR	72.7%	NA	NA	NA	70%	NA	NA	87.5%	NA	43.8*	20.3%*	NA	NA	NA
Kang 2019	DA	NA	NA	100%	45.2%	55.9%*	NA	15.4%*	80.2%	NA	60*	33.8%*	NA	NA	52.0%
	SR	NA	NA	0%	61.2%	65%*	NA	35.6%*	82.1%	NA	65*	25.5%*	NA	NA	55.5%
Turk 2019	DA	75%	98%	100%	32%	83%	NA	NA	92%	38%	25*	21%	3%	6%	52%
	SR	74	86%	85%	43%	81%	NA	NA	89%	29%	35*	NA	2%	6%	50%

*Indicates statistically significant difference.

AC-LVO, anterior circulation large vessel occlusion; BGC, balloon guided catheter; DA, distal aspiration; ENT, embolization in new territory; FPE, first pass effect; ID, inner diameter; mRS, modified Rankin scale; NA, not available; sICH, symptomatic intracranial hemorrhage; SR, stent retriever; TICI, Thrombolysis in Cerebral Infarction.

Table 3 Angiographic and clinical outcomes in patients with M2 occlusions treated with DA or SR as first-line device

Ref	Device	% catheter with ID >0.068	% with aspiration			After first line			At the end			Median procedural time (min)	% use of rescue therapy	Complications		% mRS 0–2	% mRS 6
			% with aspiration	% with BGC	% TICI >2b	% TICI >2b	% TICI 3	% FPE	% TICI >2b	% TICI 3	% TICI 3			ENT	sICH		
Mokin 2017	DA	NA	100%	NA	64.7%	45%	NA	NA	84%	59%	59%	40	45.1%	NA	NA	53%	16%
	SR	NA	56%	47%	NA	NA	NA	NA	87%	52%	52%	45	12.9%	NA	NA	60%	21%
Kim 2017	DA	0%	100%	100%	64%	NA	NA	NA	72%	NA	NA	16	20%	0%	4%	84%	0%
	SR	0%	100%	100%	81.2%	NA	NA	NA	87.5%	NA	NA	15.5	12.5%	0%	0%	75%	6.2%
Gory 2018	DA	NA	100%	NA	64.6%	29.2%	NA	NA	89.6%	35.4%	35.4%	41	31.3%	4.2%	6.3%	54.4%	19.6%
	SR	0%	NA	NA	67.7%	38.7%	NA	NA	83.9%	41.9%	41.9%	50	19.4%	0%	3.2%	50%	3.3%

BGC, balloon guided catheter; DA, distal aspiration; ENT, embolization in new territory; FPE, first pass effect; ID, internal diameter; mRS, modified Rankin scale; NA, not available; sICH, symptomatic intracranial hemorrhage; SR, stent retriever; TICI, Thrombolysis In Cerebral Infarction.

Table 4 Angiographic and clinical outcomes in patients with AC-LVO treated with DA or combined therapy as first-line device

Ref	Device	% M1 occlusion	% catheter with ID >0.068	% with aspiration	% with BGC	After first line			At the end			Median or mean procedural time (min)	% use of rescue therapy	Complications		% mRS 0–2	% mRS 6
						% TICI >2b	% TICI >2b	% FPE	% TICI >2b	% TICI 3	% TICI 3			ENT	sICH		
Türk 2014	DA	74.9%	0%	100%	0%	41.7%*	NA	NA	78.5%	28.5%*	28.5%*	85.1*	NA	NA	NA	36.4%	NA
	DA+SR	0%	0%	100%	0%	70.1%*	NA	NA	77.8%	59.3%*	59.3%*	51.6*	NA	NA	NA	50.0%	NA
Delgado 2015	DA	47%	0%	100%	0%	NA	NA	NA	89%	NA	NA	50	28.9%	4%	2%	56%*	18%
	DA+SR	66%	0%	100%	0%	NA	NA	NA	84%	NA	NA	51	12.7%	2%	13%	31%*	29%
Hesse 2017	DA	60%	NA	NA	NA	NA	NA	17%	73%	27.5%	27.5%	49	34%	11.6%	7.0%	NA	NA
	SR	65%	NA	NA	NA	NA	NA	14%	65%	19%	19%	62	10%	9.8%	5.1%	NA	NA
	DA+SR	53%	NA	NA	NA	NA	NA	26%	86%	37.5%	37.5%	55	NA	6.6%	9.2%	NA	NA
Nogueira 2018	DA	61%	0%	100%	NA	69.8%	NA	NA	77.3%	NA	NA	39	NA	NA	5.0%	45.8%	26.0%
	DA+SR	66.3%	100%	100%	NA	81.9%	NA	NA	87.4%	NA	NA	45	NA	NA	3.1%	45.3%	19.4%
Brehm 2019	DA	50%	62.2%	100%	0%	NA	NA	NA	75%*	22.2%	22.2%	55.6	30.6%	12.5%	4.2%	NA	NA
	DA+SR	58.6%	100%	100%	0%	NA	NA	NA	93.5%*	28.3%	28.3%	52.1	2%	3%	5.2%	NA	NA

* Indicates statistically significant difference.

AC-LVO, anterior circulation large vessel occlusion; BGC, balloon guided catheter; DA, distal aspiration; ENT, embolization in new territory; FPE, first pass effect; ID, inner diameter; mRS, modified Rankin scale; NA, not available; sICH, symptomatic intracranial hemorrhage; SR, stent retriever; TICI, Thrombolysis In Cerebral Infarction.

the potential superiority for the combined approach in carotid “T” occlusions as well as provide more information on the potential increased hemorrhagic risk of combined treatment.⁶²

Medium vessel occlusions

Only one study has directly compared DA and SR as the first-line approach in patients with MeVOs.¹⁴ In this retrospective study of 137 patients, the use of a 3 mm Trevo stent (Stryker Neurovascular, Fremont, CA) compared to Penumbra 3MAX device (Penumbra, Alameda, CA) resulted in higher rates of first-pass mTICI 2b–3 reperfusion and lower utilization of adjuvant therapy.¹⁴

Basilar artery occlusions

Five studies, including two prospective registries with retrospective analysis^{12,63} and two retrospective studies,^{11,64,65} have compared DA and SR approaches as first-line strategies in patients with BAOs. These five studies are summarized in a recent meta-analysis.⁶⁶ The pooled results suggested that the DA approach achieved a significantly higher rate of successful recanalization (OR 2.0, 95%CI 1.1 to 3.5; $p=0.02$) with a lower ENT rate compared with first-line SR.⁶⁶ A similar trend was found for the mTICI 3 rate.⁶⁶ Again, procedure duration was significantly lower with DA than SR.⁶⁶ However, once again, these angiographic outcomes were not associated with better clinical outcomes.⁶⁶ No significant difference for hemorrhagic complications, functional independence or mortality at 3 months was found between the two techniques.

CHALLENGES AND FUTURE PROSPECTS

New, larger aspiration catheters and vacuum aspiration systems with higher aspiration force are under development. The Penumbra JET 7 catheter (Penumbra, Alameda, CA) (with 0.072 inch ID), AXS Vecta (Stryker Neurovascular, Fremont, CA), the React catheter (Medtronic Neurovascular, Irvine, CAA) (with 0.071 inch ID) and the Penumbra Jet Engine (Penumbra, Alameda, CA) have been recently approved by the US Food and Drug Administration.^{30,67} It is, however, important to note that the largest aspiration catheters (JET 7, Vecta and React 071) are not compatible with current BGCs. A novel aspiration catheter system, the R4 Q aspiration catheter (MIVI Neuroscience, Inc, Eden Prairie, MN) has a larger proximal ID, and in a recent benchtop study demonstrated a substantial increase in aspirated flow rate and suction force compared with the commercially available standard tubular catheters.⁶⁸ As a final example, the Advanced Thrombectomy System (ANCD) is a novel stroke thrombectomy device incorporating a coated self-expanding funnel. Theoretically, this funnel must be deployed after SR expansion to the proximal part of the clot and might restrict the flow and enhance the aspiration force. Altogether, this new device might facilitate clot retrieval and reduce clot fragmentation.⁶⁹ The combination of these new generation aspiration catheters and vacuum aspiration systems may produce a higher aspiration force and tip suction forces and further improve recanalization rates with DA.³⁰ Although this new generation of large-bore aspiration catheters appears to be efficient and safe based on recent non-controlled observation studies,^{70–72} concerns exist regarding the navigability and trackability of these devices, especially around the ophthalmic artery in tortuous vessels. For example, the use of Vecta⁷² or React⁷¹ catheters required the use of an SR to deliver the aspiration catheter up to the clot level (the “grappling hook technique”) in about 25% of cases. By comparison, this “grappling hook technique” was required in 40% of cases with the ACE 068. Further studies are needed to better investigate the efficiency and safety of this new generation of aspiration catheters and vacuum aspiration systems.

Although the benefit of MT in MeVOs is suggested in several non-controlled observational studies (mainly in patients with M2 occlusions), these findings need to be confirmed in RCTs.⁴¹ MeVOs (M2 or M3 segments of the MCA, pericallosal artery or the posterior cerebral artery) can lead to severe AIS. While these smaller vessels can still cause a severe deficit, thrombectomies in these vascular beds raise some questions. The risk of vessel perforation is perceived to be higher given the smaller caliber of artery, yet it is actually unknown. It is also unclear whether medical therapy is superior to endovascular therapy in terms of clinical outcomes. Once again, the use of DA will need to be assessed in this specific scenario.

Finally, given the several limitations in the aforementioned cited literature and the rapid evolution of suction equipment, further randomized trials are required in order to better assess the efficiency of DA compared with SR or the combined approach. The research community may want to reconsider the optimal outcome metric for evaluating thrombectomy devices. The three trials mentioned above have used three different outcomes as their primary endpoint. A clinical outcome was used in COMPASS (clinical functional outcome at 90 days) and an angiographic outcome was used in both ASTER (mTICI 2b or 3) and the trials by Nogueira *et al* (mTICI 2 or 3). Clinical outcome after MT depends on multiple factors besides recanalization, including, but not limited to, patient age, comorbidities, initial infarct volume and occurrence of sICH. Moreover, although improvements in thrombectomy devices have led to a sharp increase in successful reperfusion rates, clinical outcomes have remained largely unchanged. For example, the recent COMPASS trial reported successful reperfusion in 90% of enrolled patients, yet the percentage of patients with functional independence at 90 days is only 50%.¹⁶ Thus clinical outcomes do not appear to be the optimal endpoint to capture the efficacy of thrombectomy devices. Although angiographic outcomes may represent a useful surrogate endpoint, the definition of successful revascularization should be reviewed. Recent RCTs have reported successful reperfusion (mTICI $\geq 2b$) in up to 90% of enrolled patients.¹⁶ Given these current rates of revascularization, if we use the somewhat broad “mTICI 2b or more” as the primary outcome to judge new devices, it may be unrealistic to expect higher rates of successful recanalization. Perhaps stricter parameters such as near complete (mTICI 2c or 3), complete reperfusion (mTICI 3)⁷³ or first pass effect^{74,75} rates should be used as the new standard definition for technical success in future trials.

CONCLUSION

Direct aspiration is a fast, safe and efficient thrombectomy technique that deserves its place in the interventional neuroradiology armamentarium. Given the rapid evolution of DA equipment and the inherent limitations to the many studies gathered in our review, we believe further randomized trials are needed to better capture the true efficiency of DA compared with SR and the combined approach. Rates of near complete recanalization and first pass effect should be used as the new standard definitions for technical success in these future trials.

Author affiliations

¹Interventional Neuroradiology, Fondation Ophtalmologique Adolphe de Rothschild, Paris, Île-de-France, France

²Department of Medicine – Division of Neurology, Ottawa Hospital, Ottawa, Ontario, Canada

³Neurology Department, Hôpital Foch, Suresnes, Île-de-France, France

⁴Université de Paris, Paris, Île-de-France, France

⁵Department of Medicine – Division of Neurology, Royal Columbian Hospital, New Westminster, British Columbia, Canada

⁶Diagnostic and Interventional Neuroradiology, Centre Hospitalier Universitaire de Nancy, Nancy, France

⁷Neurology Stroke Unit, University Hospital Centre Nancy, Nancy, France

Correction notice Since the online publication of this article, the Provenance and peer review statement was updated from 'Not commissioned; externally peer reviewed' to 'Commissioned; externally peer reviewed.'

Contributors Study design: WB, SE, RF, RB. Acquisition, analysis, or interpretation of data: WB, SE, RF, RB. Drafting of the manuscript: All authors. Supervision: RB.

Funding The authors have not declared a specific grant for this research from any funding agency in the public, commercial or not-for-profit sectors.

Competing interests None declared.

Patient consent for publication Not required.

Provenance and peer review Commissioned; externally peer reviewed.

ORCID iDs

Robert Fahed <http://orcid.org/0000-0002-1887-5097>

Stanislas Smajda <http://orcid.org/0000-0002-6486-1710>

François Delvoe <http://orcid.org/0000-0002-0697-2156>

Benjamin Gory <http://orcid.org/0000-0001-8424-4464>

Michel Piotin <http://orcid.org/0000-0002-1354-4328>

Raphaël Blanc <http://orcid.org/0000-0002-3975-3865>

REFERENCES

- Berkhemer OA, Fransen PSS, Beumer D, et al. A randomized trial of intraarterial treatment for acute ischemic stroke. *N Engl J Med* 2015;372:11–20.
- Bracard S, Ducrocq X, Mas JL, et al. Mechanical thrombectomy after intravenous alteplase versus alteplase alone after stroke (THRACE): a randomised controlled trial. *Lancet Neurol* 2016;15:1138–47.
- Powers WJ, Rabinstein AA, Ackerson T, et al. Guidelines for the early management of patients with acute ischemic stroke: 2019 update to the 2018 guidelines for the early management of acute ischemic stroke: a guideline for healthcare professionals from the American Heart Association/American Stroke Association. *Stroke* 2019;50:STR.0000000000000211.
- Turc G, Bhogal P, Fischer U, et al. European Stroke Organisation (ESO) - European Society for Minimally Invasive Neurological Therapy (ESMINT) guidelines on mechanical thrombectomy in acute ischemic stroke. *J Neurointerv Surg* 2019;neurintsurg-2018-014569.
- Turk AS, Spiotta A, Frei D, et al. Initial clinical experience with the ADAPT technique: a direct aspiration first pass technique for stroke thrombectomy. *J Neurointerv Surg* 2014;6:231–7.
- Delgado Almandoz JE, Kayan Y, Wallace AN, et al. Larger ACE 68 aspiration catheter increases first-pass efficacy of ADAPT technique. *J Neurointerv Surg* 2019;11:141–6.
- Lapergue B, Blanc R, Guedin P, et al. A direct aspiration, first pass technique (ADAPT) versus stent retrievers for acute stroke therapy: an observational comparative study. *AJNR Am J Neuroradiol* 2016;37:1860–5.
- Mokin M, Setlur Nagesh SV, Ionita CN, et al. Comparison of modern stroke thrombectomy approaches using an in vitro cerebrovascular occlusion model. *AJNR Am J Neuroradiol* 2015;36:547–51.
- Peschillo S, Diana F, Berge J, et al. A comparison of acute vascular damage caused by ADAPT versus a stent retriever device after thrombectomy in acute ischemic stroke: a histological and ultrastructural study in an animal model. *J Neurointerv Surg* 2017;9:743–9.
- Turk AS, Campbell JM, Spiotta A, et al. An investigation of the cost and benefit of mechanical thrombectomy for endovascular treatment of acute ischemic stroke. *J Neurointerv Surg* 2014;6:77–80.
- Son S, Choi DS, Oh MK, et al. Comparison of solitaire thrombectomy and penumbral suction thrombectomy in patients with acute ischemic stroke caused by basilar artery occlusion. *J Neurointerv Surg* 2016;8:13–18.
- Gory B, Mazighi M, Blanc R, et al. Mechanical thrombectomy in basilar artery occlusion: influence of reperfusion on clinical outcome and impact of the first-line strategy (ADAPT vs stent retriever) 2018;129:1482.
- Premat K, Bartolini B, Baronnet-Chauvet F, et al. Single-center experience using the 3MAX reperfusion catheter for the treatment of acute ischemic stroke with distal arterial occlusions. *Clin Neuroradiol* 2018;28:553–62.
- Haussen DC, Eby B, Al-Bayati AR, et al. A comparative analysis of 3MAX aspiration versus 3 MM Trevo retriever for distal occlusion thrombectomy in acute stroke. *J Neurointerv Surg* 2020;12:neurintsurg-2019-014990.
- Lapergue B, Blanc R, Gory B, et al. Effect of endovascular contact aspiration vs stent retriever on revascularization in patients with acute ischemic stroke and large vessel occlusion: the ASTER randomized clinical trial. *JAMA* 2017;318:443–52.
- Turk AS, Siddiqui A, Fifi JT, et al. Aspiration thrombectomy versus stent retriever thrombectomy as first-line approach for large vessel occlusion (COMPASS): a multicentre, randomised, open label, blinded outcome, non-inferiority trial. *Lancet* 2019;393:998–1008.
- Humphries W, Hoit D, Doss VT, et al. Distal aspiration with retrievable stent assisted thrombectomy for the treatment of acute ischemic stroke. *J Neurointerv Surg* 2015;7:90–4.
- Massari F, Henninger N, Lozano JD, et al. ARTS (Aspiration-Retriever Technique for Stroke): initial clinical experience. *Interv Neuroradiol* 2016;22:325–32.
- Maus V, Behme D, Kabbasch C, et al. Maximizing first-pass complete reperfusion with SAVE. *Clin Neuroradiol* 2018;28:327–38.
- Hesse AC, Behme D, Kemmling A, et al. Comparing different thrombectomy techniques in five large-volume centers: a 'real world' observational study. *J Neurointerv Surg* 2018;10:525–9.
- Nogueira RG, Frei D, Kirmani JF, et al. Safety and efficacy of a 3-dimensional stent retriever with aspiration-based thrombectomy vs aspiration-based thrombectomy alone in acute ischemic stroke intervention: a randomized clinical trial. *JAMA Neurol* 2018;75:304–11.
- Imai K, Mori T, Izumoto H, et al. Clot removal therapy by aspiration and extraction for acute embolic carotid occlusion. *AJNR Am J Neuroradiol* 2006;27:1521–7.
- Bose A, Henkes H, Alfke K, et al. The Penumbral system: a mechanical device for the treatment of acute stroke due to thromboembolism. *AJNR Am J Neuroradiol* 2008;29:1409–13.
- Penumbral Pivotal Stroke Trial Investigators. The Penumbral Pivotal Stroke Trial: safety and effectiveness of a new generation of mechanical devices for clot removal in intracranial large vessel occlusive disease. *Stroke* 2009;40:2761–8.
- Kang D-H, Hwang Y-H, Kim Y-S, et al. Direct thrombus retrieval using the reperfusion catheter of the Penumbral system: forced-suction thrombectomy in acute ischemic stroke. *AJNR Am J Neuroradiol* 2011;32:283–7.
- Mocco J, Zaidat OO, von Kummer R, et al. Aspiration thrombectomy after intravenous alteplase versus intravenous alteplase alone. *Stroke* 2016;47:2331–8.
- Heit JJ, Wong JH, Mofatt AM, et al. Sofia intermediate catheter and the SNAKE technique: safety and efficacy of the Sofia catheter without guidewire or microcatheter construct. *J Neurointerv Surg* 2018;10:401–6.
- Nikoubashman O, Alt JP, Nikoubashman A, et al. Optimizing endovascular stroke treatment: removing the microcatheter before clot retrieval with stent-retrievers increases aspiration flow. *J Neurointerv Surg* 2017;9:459–62.
- Alawieh A, Chatterjee AR, Vargas J, et al. Lessons learned over more than 500 stroke thrombectomies using ADAPT with increasing aspiration catheter size. *Neurosurgery* 2020;86:61–70.
- Yaeger K, Iserson A, Singh P, et al. A technical comparison of thrombectomy vacuum aspiration systems. *J Neurointerv Surg* 2020;12:72–6.
- Arslanian RA, Marosfoi M, Caroff J, et al. Complete clot ingestion with cyclical ADAPT increases first-pass recanalization and reduces distal embolization. *J Neurointerv Surg* 2019;11:931–6.
- Simon S, Grey CP, Massenzo T, et al. Exploring the efficacy of cyclic vs static aspiration in a cerebral thrombectomy model: an initial proof of concept study. *J Neurointerv Surg* 2014;6:677–83.
- Kang D-H, Kim BM, Heo JH, et al. Effect of balloon guide catheter utilization on contact aspiration thrombectomy. *J Neurosurg* 2018;131:1494.
- Blanc R, Redjem H, Ciccio G, et al. Predictors of the aspiration component success of a direct aspiration first pass technique (ADAPT) for the endovascular treatment of stroke reperfusion strategy in anterior circulation acute stroke. *Stroke* 2017;48:1588–93.
- Bernava G, Rosi A, Boto J, et al. Direct thromboaspiration efficacy for mechanical thrombectomy is related to the angle of interaction between the aspiration catheter and the clot. *J Neurointerv Surg* 2019;neurintsurg-2019-015113.
- Mascitelli JR, Kellner CP, Oravec CS, et al. Factors associated with successful revascularization using the aspiration component of ADAPT in the treatment of acute ischemic stroke. *J Neurointerv Surg* 2017;9:636–40.
- Ye G, Cao R, Lu J, et al. Association between thrombus density and reperfusion outcomes using different thrombectomy strategies: a single-center study and meta-analysis. *Front Neurol* 2019;10:843.
- Bourcier R, Mazighi M, Labreuche J, et al. Susceptibility vessel sign in the ASTER trial: higher recanalization rate and more favourable clinical outcome after first line stent retriever compared to contact aspiration. *J Stroke* 2018;20:268–76.
- Liebeskind DS, Sanossian N, Yong WH, et al. CT and MRI early vessel signs reflect clot composition in acute stroke. *Stroke* 2011;42:1237–43.
- Janot K, Zhu F, Kerleroux B, et al. "Adaptative endovascular strategy to the CloT MRI in large intracranial vessel occlusion" (VECTOR): study protocol of a randomized control trial. *J Neuroradiol* 2019.
- Goyal M, Ospel JM, Menon BK, et al. MeVO: the next frontier? *J Neurointerv Surg* 2020;neurintsurg-2020-015807.
- Bernsen MLE, Goldhoorn R-JB, van Oostenbrugge RJ, et al. Equal performance of aspiration and stent retriever thrombectomy in daily stroke treatment. *J Neurointerv Surg* 2019;11:631–6.
- Martini M, Mocco J, Turk A, et al. 'Real-world' comparison of first-line direct aspiration and stent retriever mechanical thrombectomy for the treatment of acute ischemic stroke in the anterior circulation: a multicenter international retrospective study. *J Neurointerv Surg* 2019;11:957–63.

- 44 Stapleton CJ, Leslie-Mazwi TM, Torok CM, *et al.* A direct aspiration first-pass technique vs stentriever thrombectomy in emergent large vessel intracranial occlusions. *J Neurosurg* 2018;128:567–74.
- 45 Kang D-H, Kim JW, Kim BM, *et al.* Need for rescue treatment and its implication: stent retriever versus contact aspiration thrombectomy. *J Neurointerv Surg* 2019;11:979–83.
- 46 Gory B, Armoiry X, Sivan-Hoffmann R, *et al.* A direct aspiration first pass technique for acute stroke therapy: a systematic review and meta-analysis. *Eur J Neurol* 2018;25:284–92.
- 47 Phan K, Dmytriw AA, Teng I, *et al.* A direct aspiration first pass technique vs standard endovascular therapy for acute stroke: a systematic review and meta-analysis. *Neurosurgery* 2018;83:19–28.
- 48 Qin C, Shang K, Xu S-B, *et al.* Efficacy and safety of direct aspiration versus stent-retriever for recanalization in acute cerebral infarction: a PRISMA-compliant systematic review and meta-analysis. *Medicine* 2018;97:e12770–e70.
- 49 Tsang COA, Cheung IHW, Lau KK, *et al.* Outcomes of stent retriever versus aspiration-first thrombectomy in ischemic stroke: a systematic review and meta-analysis. *AJNR Am J Neuroradiol* 2018;39:2070–6.
- 50 Wei D, Mascitelli JR, Nistal DA, *et al.* The use and utility of aspiration thrombectomy in acute ischemic stroke: a systematic review and meta-analysis. *AJNR Am J Neuroradiol* 2017;38:1978–83.
- 51 Boulanger M, Lapergue B, Turjman F, *et al.* First-line contact aspiration vs stent-retriever thrombectomy in acute ischemic stroke patients with large-artery occlusion in the anterior circulation: systematic review and meta-analysis. *Interv Neuroradiol* 2019;25:244–53.
- 52 Hsieh KL-C, Chuang K-I, Weng H-H, *et al.* First-line a direct aspiration first-pass technique vs. first-line stent retriever for acute ischemic stroke therapy: a meta-analysis. *Front Neurol* 2018;9:801–01.
- 53 Primiani CT, Vicente AC, Brannick MT, *et al.* Direct aspiration versus stent retriever thrombectomy for acute stroke: a systematic review and meta-analysis in 9127 patients. *J Stroke Cerebrovasc Dis* 2019;28:1329–37.
- 54 Kim Y-W, Son S, Kang D-H, *et al.* Endovascular thrombectomy for M2 occlusions: comparison between forced arterial suction thrombectomy and stent retriever thrombectomy. *J Neurointerv Surg* 2017;9:626–30.
- 55 Mokin M, Primiani CT, Ren Z, *et al.* Endovascular treatment of middle cerebral artery M2 occlusion strokes: clinical and procedural predictors of outcomes. *Neurosurgery* 2017;81:795–802.
- 56 Gory B, Lapergue B, Blanc R, *et al.* Contact aspiration versus stent retriever in patients with acute ischemic stroke with M2 occlusion in the ASTER randomized trial (contact aspiration versus stent retriever for successful revascularization). *Stroke* 2018;49:461–4.
- 57 Phan K, Maingard J, Kok HK, *et al.* Contact aspiration versus stent-retriever thrombectomy for distal middle cerebral artery occlusions in acute ischemic stroke: meta-analysis. *Neurointervention* 2018;13:100–9.
- 58 Saber H, Narayanan S, Palla M, *et al.* Mechanical thrombectomy for acute ischemic stroke with occlusion of the M2 segment of the middle cerebral artery: a meta-analysis. *J Neurointerv Surg* 2018;10:620–4.
- 59 Brehm A, Maus V, Tsogkas I, *et al.* Stent-retriever assisted vacuum-locked extraction (SAVE) versus a direct aspiration first pass technique (ADAPT) for acute stroke: data from the real-world. *BMC Neurol* 2019;19:65.
- 60 Delgado Almandoz JE, Kayan Y, Young ML, *et al.* Comparison of clinical outcomes in patients with acute ischemic strokes treated with mechanical thrombectomy using either Solumbra or ADAPT techniques. *J Neurointerv Surg* 2016;8:1123–8.
- 61 Texakalidis P, Giannopoulos S, Karasavvidis T, *et al.* Mechanical thrombectomy in acute ischemic stroke: a meta-analysis of stent retrievers vs direct aspiration vs a combined approach. *Neurosurgery* 2019;372:nyz258.
- 62 Lapergue B, Labreuche J, Blanc R, *et al.* Combined use of contact aspiration and the stent retriever technique versus stent retriever alone for recanalization in acute cerebral infarction: the randomized aster 2 study protocol. *J Neurointerv Surg* 2020;12:471–6.
- 63 Kang D-H, Jung C, Yoon W, *et al.* Endovascular thrombectomy for acute basilar artery occlusion: a multicenter retrospective observational study. *J Am Heart Assoc* 2018;7:e009419.
- 64 Gerber JC, Daubner D, Kaiser D, *et al.* Efficacy and safety of direct aspiration first pass technique versus stent-retriever thrombectomy in acute basilar artery occlusion-a retrospective single center experience. *Neuroradiology* 2017;59:297–304.
- 65 Mokin M, Sonig A, Sivakanthan S, *et al.* Clinical and procedural predictors of outcomes from the endovascular treatment of posterior circulation strokes. *Stroke* 2016;47:782–8.
- 66 Ye G, Lu J, Qi P, *et al.* Firstline a direct aspiration first pass technique versus firstline stent retriever for acute basilar artery occlusion: a systematic review and meta-analysis. *J Neurointerv Surg* 2019;11:740–6.
- 67 Gross BA, Jadhav AP, Jovin TG, *et al.* Clinical comparison of new generation 0.071-inch and 0.072-inch aspiration catheters. *World Neurosurg* 2019;130:e463–6.
- 68 Long TD, Kallmes DF, Hanel R, *et al.* Novel aspiration catheter design for acute stroke thrombectomy. *J Neurointerv Surg* 2019;11:190–5.
- 69 Sanchez S, Cortiñas I, Villanova H, *et al.* Ancd thrombectomy device: in vitro evaluation. *J Neurointerv Surg* 2020;12:77–81.
- 70 Hassan A, Fifi J, Zaidat O. Efficacy and safety of mechanical thrombectomy using larger bore jet 7 aspiration catheters for intracranial large vessel occlusion. *J NeuroIntervent Surg* 2019;11:A126–A26.
- 71 Raymond SB, Nasir-Moin M, Koch MJ, *et al.* Initial experience with react 68 aspiration catheter. *Interv Neuroradiol* 2020;159101991989892 (published Online First: 2020/01/24).
- 72 Satti S, Sivapatham T, Almallouhi E, *et al.* Vecta 071 and 074 large bore aspiration catheter: initial multi-center experience. *J NeuroIntervent Surg* 2019;11:A114–5.
- 73 Rizvi A, Seyedsaadat SM, Murad MH, *et al.* Redefining 'success': a systematic review and meta-analysis comparing outcomes between incomplete and complete revascularization. *J Neurointerv Surg* 2019;11:9–13.
- 74 Zaidat OO, Castonguay AC, Linfante I, *et al.* First pass effect: a new measure for stroke thrombectomy devices. *Stroke* 2018;49:660–6.
- 75 Ducroux C, Plotin M, Gory B, *et al.* First pass effect with contact aspiration and stent retrievers in the aspiration versus stent retriever (ASTER) trial. *J Neurointerv Surg* 2020;12:neurintsurg-2019-015215.